

HISTOLOGICAL ALTERATIONS OF ASIAN SEA BASS (*Lates calcarifer*, BLOCH) DURING SUBLETHAL CADMIUM EXPOSURE.

Chutima Thanomsit^{1*}, Tiantip Boonchuay¹, Phochit Nanthanawat²
and Praparsiri Kanchanopas-Barnette^{1,3,4}

¹Environmental Science Program, Faculty of Science, Burapha University, Chon Buri 20131, Thailand.

²Department of Biotechnology, Faculty of Science, Burapha University, Chon Buri 20131, Thailand

³Department of Aquatic Science, Faculty of Science, Burapha University, Chon Buri 20131, Thailand.

⁴Center of Excellence on Environmental Health and Toxicology, Phaya Thai, Bangkok, 10400, Thailand.

ABSTRACT

The aim of this study was to investigate histological alterations in Asian sea bass (*Lates calcarifer*, Bloch) after exposed to cadmium in different doses (2, 4, and 6 mg/kg of cadmium) and time courses (24, 48, and 72 h). Histological changes tested were gill, liver, intestine, stomach, and kidney. We found that there were several damages in gill, such as edema, hyperplasia, epithelial lifting, and partial fusion of secondary lamellae, vacuole degeneration, enlargement of sinusoid and necrosis of hepatocytes in liver, the increasing and swelling of goblet cells and cell lesion in stomach and intestine, and degenerations of tubular, melano-macrophage aggregate, an increase of Bowman's space, vacuole degeneration, and necrotic areas in kidney. The highest degree of injury index exhibited in kidney with significant difference from gill and liver. In addition, at 6 mg/kg cadmium exposure for 72 h, melano-macrophage and pigmented macrophage counting showed the highest value of 170 ± 3 . In conclusion, we found that histological alterations in Asian sea bass were clearly caused by cadmium exposure depended upon exposure time and dose response.

Keywords: Histology, cadmium, Asian sea bass, injury index

INTRODUCTION

Cadmium is one of important toxic substances in the aquatic environment. More than 90% of cadmium contaminated in the environment is caused by anthropogenic activities, such as smelting operation, electroplating, commercial fertilizer, and pesticide used in agriculture. Cadmium is a non-degradable element and its toxicity effect can last for a long time. When enter to aquatic environment, cadmium can accumulate and cause many effects in organisms including fish. Fish can uptake cadmium either directly from water by passive diffusion of gill or indirectly from food by the ingestion and absorption in the intestine. Wherever its uptake, cadmium will circulate to liver and kidney for detoxification and excretion process (Kumar and Shingh, 2010). The accumulation of cadmium in fish is of concern because fish is one of important human food sources; most fishes are on the top of food chain, and so they tend to accumulate higher concentration of cadmium in their bodies (Ruangsomboon and Wongrat, 2006).

Cadmium has been reported to cause many effects on fish even at low concentration and in an acute or chronic exposure. It has been shown that alterations occurred in several organs, i.e., kidney damage, malformations of spleen, morphological and biochemical changes in gill, and suppression of immune system that affects the fish health (Okocha and Adedeji, 2011). The major cadmium accumulation organs in fish are liver, gill, kidney, gastrointestinal tract, and muscle that can cause the changes of these organs (Brucka-Jastrzebska and Protasowicki, 2006; Jayakumar and Paul, 2006; Wangsongsak et al., 2007; Vinodhini and Narayanan, 2008).

Histological alteration has been used as an indicator for the exposure of organisms to stressors or pollutants in the environment. This method has an advantage because it gives the obvious results of the change in specific targeted organs or cells in vivo. Histological effect is one of the rapid, reliable, and inexpensive methods for investigation of both acute and chronic exposure of animals in the field (Hinton et al., 1992). However, the effects of cadmium on fish histopathology were mostly observed in

freshwater fish and sea fish, while in brackish water fish, few studies had been reported. Asian sea bass (*Lates calcarifer*, Bloch) is a brackish water fish in family *Latidae* that inhabits coastal waters, estuaries, lagoons and rivers along the Indo-West Pacific regions. It is an economically important food fish in the tropical and subtropical regions of Asia and the Pacific, especially in Thailand, Malaysia, Singapore, Indonesia, Hong Kong, and Taiwan (Cheong, 1989), and also in Australia (Athauda et al., 2012). Most Asian sea bass farms in Thailand are located in the estuaries area causing the risk to cadmium exposure and accumulation. The effect of cadmium exposure on brackish water fish has been inadequate studied.

The aim of this study was to investigate the histological alterations of Asian sea bass organs, i.e., gills, liver, intestine, stomach, and kidney after exposed to different concentrations of cadmium and times of exposure.

MATERIALS AND METHODS

Animal husbandry and cadmium treatment

Healthy juvenile Asian sea bass were collected from farms at Angsila, Chon Buri Province. The animals were maintained in 2,000-L tanks of freshwater, aerated at 25 °C and acclimated for seven days with no feeding during the research period. After acclimation, juvenile Asian sea bass (n=5) with an average body weight of 112 ± 5 g and length of 15 ± 1.1 cm was intra-peritoneal injected with CdNO₃ dissolved in 50 mM sodium phosphate buffer, pH 7.4, to a final concentrations of 2, 4, and 6 mg CdNO₃/kg. Each five fishes were used as the control group (non-treated), and vehicle control group, which were injected with the same volumes of buffer solution without cadmium. Fishes were maintained in each 20-L tank and killed after 24, 48, and 72 h cadmium exposure. Then, fishes were subsequently placed in 10% phosphate buffer formalin for fixation.

Histological analysis

The fish tissues, i.e., liver, gill, intestine, stomach, and kidney of the control group, vehicle control group, and cadmium treated fish group were

cut into small pieces and fixed in 10% phosphate buffer formalin solution for 24 h. Tissues were dehydrated in a graded series of ethanol, i.e., 50%, 70%, 80%, 90%, and absolute ethanol, respectively. The dehydrated tissues were subsequently cleared with xylene, infiltrated, and embedded in paraffin. Histological sections were cut into a 6- μ m thickness sample and stained with hematoxylin and eosin. The changes in tissue were observed and analyzed under the light compound microscope (Primo Star, ZEISS) and photographed by digital camera (Nikon coolpix S 5100).

Histological record

Morphological damages were recorded according to the injury index described by Bernet et al. (1999) with the slight modification. The morphological changes that observed in liver, gill, and kidney were classified in four severity factors, i.e., unchanged (0), mild occurrence (1), moderate occurrence (2), and severe occurrence (3). The injury index was assessed following the application of a mathematical equation instituted for each group of lesion in each organ, as follows:

$$\text{Injury organ index (Iorg)} = \sum_{rp} \sum_{alt} (a_{org rp alt} \times w_{org rp alt})$$

Where: **org** was represented for organ (constant); **rp** was represented for the reaction pattern, **alt** was represented for the alteration, **a** was represented for the score value, and **w** was represented for the importance factor (Bernet et al. 1999). All changes were classified into four categories, i.e., unchanged (0) was equivalent to that was changed less than 10%, mild occurrence (1) was equivalent to the changes that occurred between 10 - 30%, moderate occurrence (2) was equivalent to the changes that occurred between 31-70%, and severe occurrence (3) was equivalent to the changes that occurred between 71-100%.

Melano-macrophage center (MMC) and pigmented macrophage analysis

The MMC and pigmented macrophage in kidney sections of five fishes were studied under light compound microscope (40x). MMC and pigmented macrophages in sections of each fish

were recorded using an eyepiece graticule coupled to a light compound microscope, then, an average count was determined and results were expressed as units per mm², as described by Aguis and Roberts (1981).

Statistical analysis

The statistical analysis of the histological records where the differences of MMC and pigmented macrophage in kidney were evaluated by a two-way analysis of variance (ANOVA) procedure using SPSS 10 for window software, significant differences were considered at $p < 0.05$. Descriptive statistics (mean and standard error) were performed on all parameters, comprising time and dose response.

RESULTS

Histological alterations

Gills

A normal gill tissue was composed of three parts, i.e., gill arch, gill filament, and gill lamellae, as shown in figure 1 A. The formation of edema cells that caused epithelial lifting, hyperplasia, and partial fusion of lamellae was observed after Asian sea bass exposed to cadmium (figures 1 B-D). This severity of alteration occurred in accordance to the higher levels and longer time of cadmium exposure.

Livers

The hepatocytes from the control group of Asian sea bass were characterized by circular shape and had nucleus in the center of the cells (figure 2 A). The alterations of liver cells occurred through enlargement of sinusoids, vacuolar degradation, and necrosis of hepatocyte after exposure to cadmium, as shown in figures 2 B to D, whereas those occurred in liver tissues of Asian sea bass, which exposed to cadmium at 2 mg/kg are shown in Figure 2 B. It was found that the cell shape and characteristics of nucleus had some minor changes from those of the control group and the vehicle control group (data not shown). The alterations that occurred in liver tissues of Asian sea bass, which exposed to 4 (Figure 2 C) and 6 mg/kg (Figure 2 D) of cadmium concentrations, respectively, showed that there was an increasing in vacuole degrada-

tion for the group subjected to more than 2 mg/kg cadmium exposures. Asian sea bass exposed to 6 mg/kg cadmium concentration for 72 h

was found to have necrosis of cells, as shown in Figure 2 D.

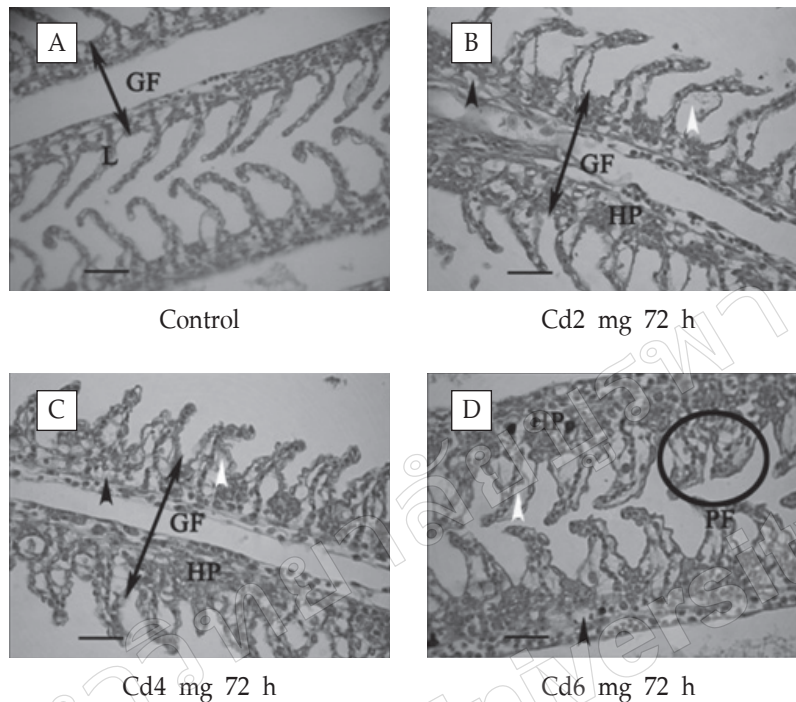


Figure 1. Showing histological alterations in gill tissue of Asian sea bass in the control group (A), fishes exposed to cadmium at 2 (B), 4 (C) and 6 (D) mg/kg, respectively for 72 h, where GF was represented for Gill filament, L was represented for lamellae, white arrow pointing at epithelial lifting, black arrow pointing at edema, PF was represented for partial fusion of the lamellae, HP was represented for hyperplasia, and scale bars = 25 μm .

Intestine

Tissue alterations were began to observe as swelling and increasing of goblet cells after exposure to 2 mg/kg cadmium concentration, as shown in Figure 2 B. Tissue alterations were more progress in tissues of the groups that exposed to 4 and 6 mg/kg of cadmium, respectively, such as the appearance of wounds, and cell lesions, i.e., laceration of the intestine cells, as shown in Figures 2 C to D.

Stomach

Histological analysis of Asian sea bass revealed the normality of stomach tissues in both of the control (Figure 4 A) and vehicle control

groups (data not shown). It suggested that the presence of mucous secreting cells with pink-violet coloration was observed without lesion, and wounds were observed in other parts of the tissues. On the other hand, wounds near cells in different parts and cells lesion were observed in the cadmium-exposed group. Fishes exposed to cadmium at 2 mg/kg concentration had the least alterations, as shown in Figure 4 B, while those groups that exposed at the concentrations of 4 and 6 mg/kg showed an increasing in tissue alterations according to an increasing in the cadmium concentration and the time course of exposure. Results are summarized in Figures 4 C and D.

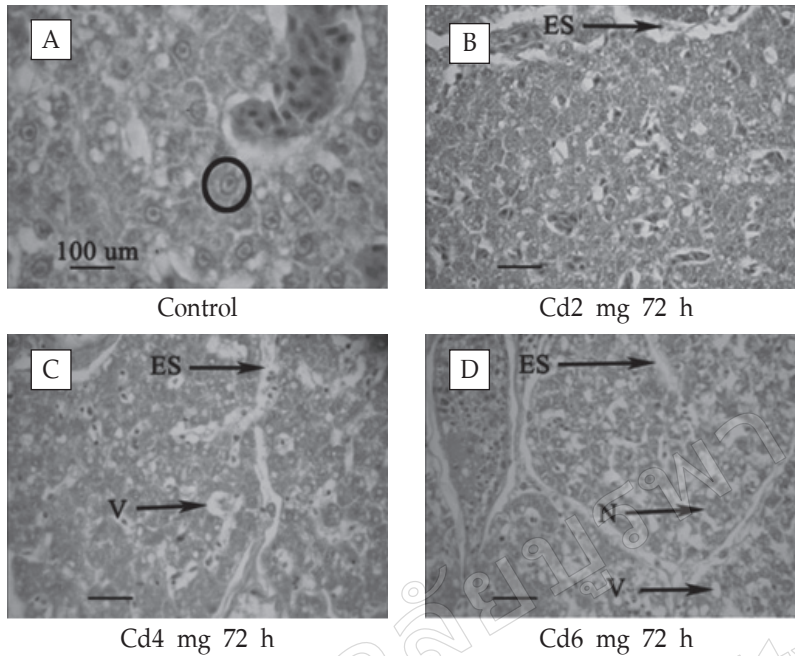


Figure 2. Showing histological alterations in liver tissues of Asian sea bass in the control group (A) and the group that exposed to cadmium with 2 (B), 4 (C), and 6 (D) mg/kg for 72 h, respectively, where S was represented for sinusoid, ES was represented for enlargement of sinusoid, V was represented for vacuolation, N was represented for necrosis, and scale bars = 25 μm

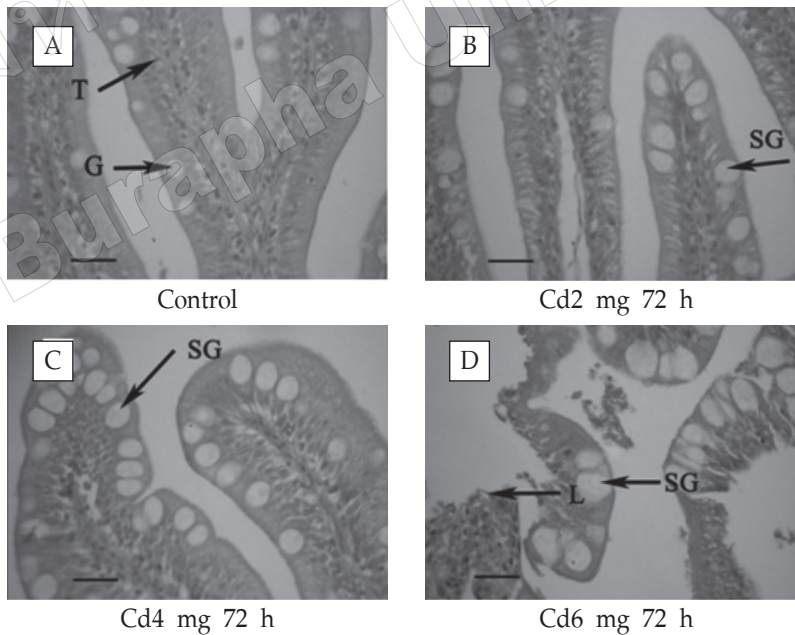


Figure 3. Showing histological alterations in intestine tissues of Asian sea bass in the control group (A), and the groups that had been exposed to cadmium at 2 (B), 4 (C), and 6 (D) mg/kg for 72 h, respectively, where M was represented for microvillus, G was represented for goblet cell, SG was represented for swelling of goblet cell, T was represented for tall cylindrical villi, L was represented for lesion, and scale bars = 25μm.

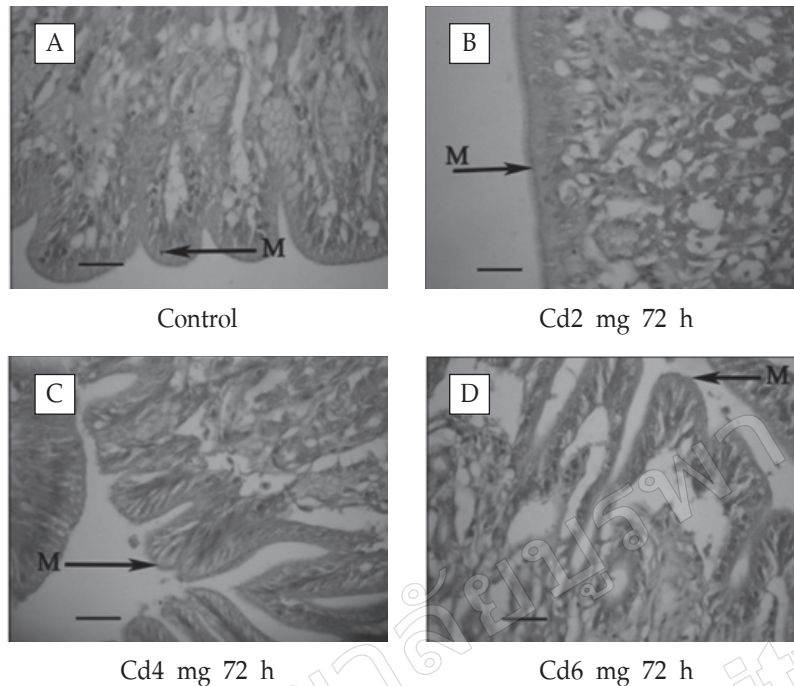


Figure 4. Showing histological alterations in intestine tissues of Asian sea bass in the control group (A) and those groups exposed to cadmium at 2 (B), 4 (C), and 6 (D) mg/kg for 72 h, respectively, where M was represented for mucous secreting cell, L was represented for lesion, scale bars = 25 μ m.

Kidney

The normal characteristics of cells in kidney were composed of glomeruli and tubules in an organized compartment. The alterations of kidney cells were observed in fishes that exposed to cadmium at the concentration of 2 mg/kg. The tubular epithelium shape was deformed and the vacuole was generated, as shown in Figure 5 B. These alterations for Asian sea bass exposed to cadmium at 4 and 6 mg/kg were increased intensively, which in turn created vacuolation in kidney cells throughout the period of study. It was also found that the Bowman's space was increased, whereas necrosis was observed in some parts of tissues in those groups of fishes that exposed to cadmium at 4 and 6 mg/kg, as shown in Figures 5 C and D.

Histological records

The histological alterations in gill, liver, kidney of Asian sea bass, and injury index were observed at 24, 48, and 72 h after exposed to cadmium at

2, 4, and 6 mg/kg. The alteration lesions were observed in gill, liver, and kidney throughout the experimental periods. The injury index in Asian sea bass is summarized in Figure 6. The result showed that both of cadmium concentrations and times of exposure did affect the injury index. Cadmium concentrations and times of exposure, which induced the highest injury index in kidney showed the significant different from liver and gill. The detected highest injury index was 11.97 ± 0.4 in fishes exposed to cadmium at 6 mg/kg for 72 h, which was approximately eight times higher than those of the control and vehicle control groups, whereas the lowest injury index was 4.0 ± 0.1 in fishes exposed to cadmium at 2 mg/kg for 24 h. The injury index of fishes that exposed to all cadmium concentrations and times of exposure was significantly different from those of the control and vehicle control groups at 95% confidence, whereas there was no significant different between those that exposed to cadmium for 24, 48, and 72 h in each concentration.

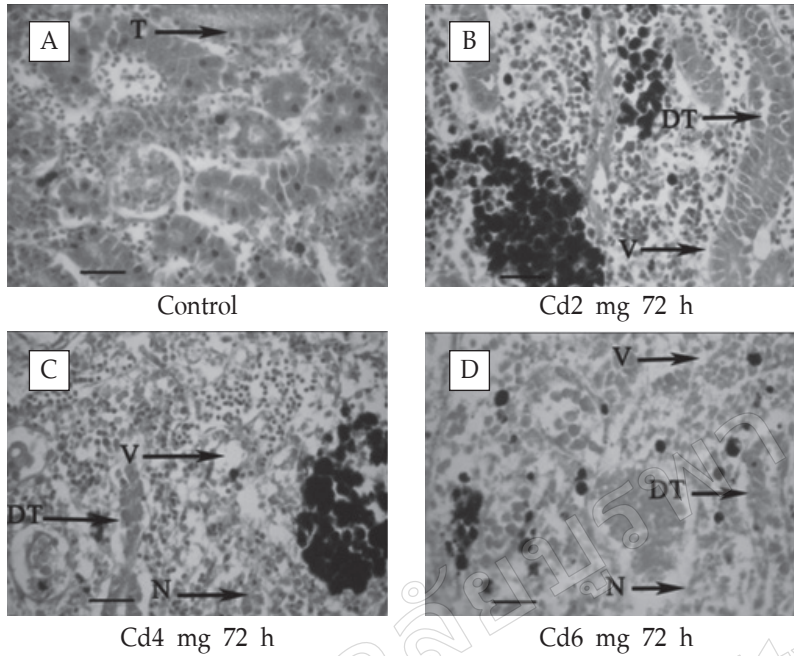


Figure 5. Showing histological alterations in intestine tissues of Asian sea bass in the control group (A) and those groups that exposed to cadmium at 2 (B), 4 (C), and 6 (D) mg/kg for 72 h, respectively, where T was represented for tubular epithelium, BI was represented for Bowman’s space increase, MG was represented for Melanomacrophage aggregate, DT was represented for degeneration of tubular, V was represented for vacuolation, N was represented for necrosis, scale bars = 25 μm.

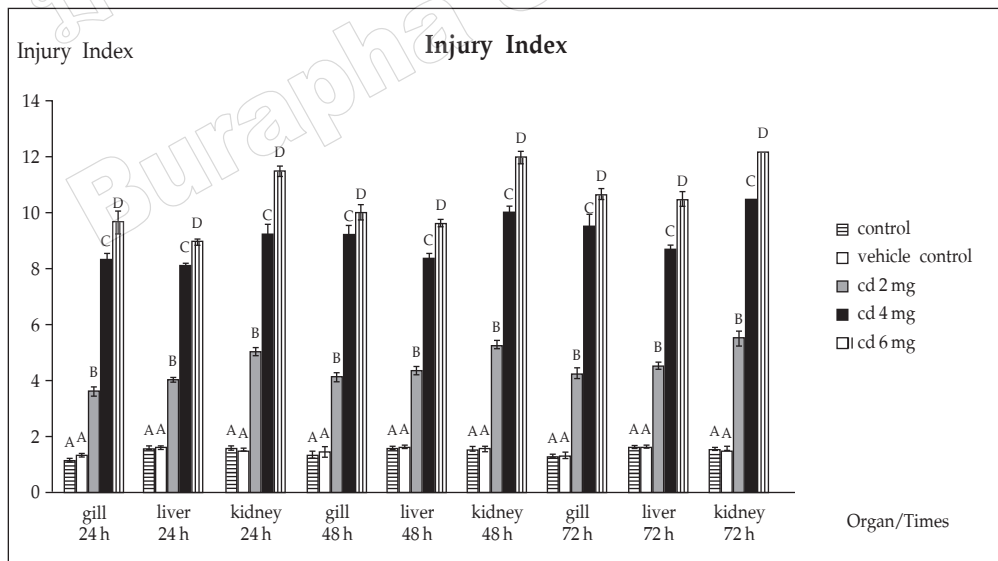


Figure 6. Summary of tissue damages showing injury index of gill, liver and kidney in Asian sea bass (*Lates calcarifer*, Bloch) exposed to cadmium at the concentrations of 2, 4, and 6 mg/kg for 24, 48, and 72 h, respectively. The different letters shown on the graph represented for the various studied groups and different statistically significant levels, where the values of mean ± SE at 95% were statistically significant at the level p <0.05.

Melanomacrophage center (MMC) and pigmented macrophage analysis

MMC and pigmented macrophage counting were recorded to assess kidney alterations in Asian sea bass exposed to cadmium at the concentrations of 2, 4, and 6 mg/kg for 24, 48 or 72 h, respectively. The result showed that both the concentration of cadmium and the time of exposure affected on MMC and pigmented macrophage counting. The highest

MMC and pigmented macrophage counting were 172 ± 3 at 6 mg/l cadmium after 72 h, which was 1.9 times higher than those of the control and vehicle control groups. MMC and pigmented macrophage counting for all cadmium concentrations in all times of exposure were significant different as compared to those of the control and vehicle control groups with 95% confidence ($p < 0.05$). However, there was no significant alteration occurred as compared each exposure time.

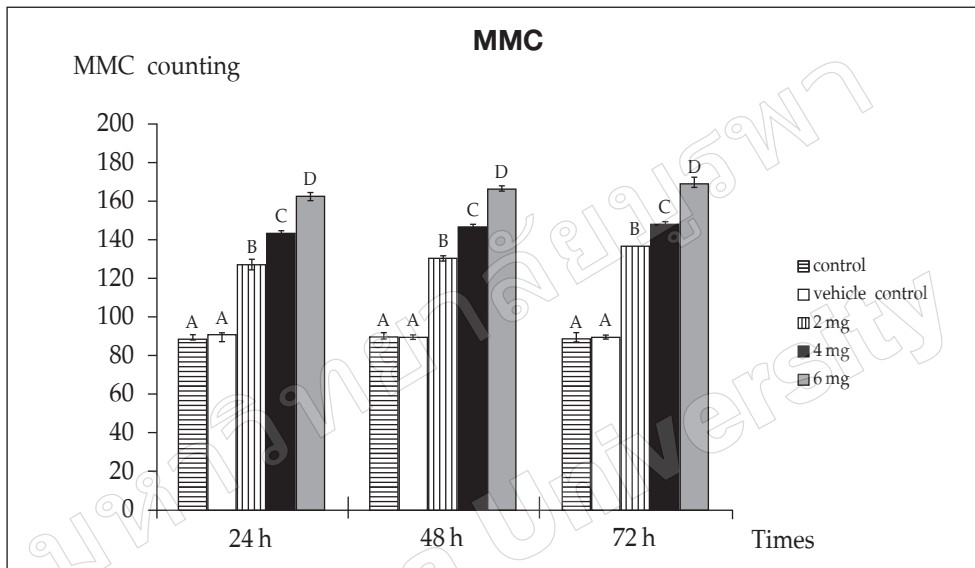


Figure 7. Showing MMC and pigmented macrophage counting in Asian sea bass (*Lates calcarifer*, Bloch) kidney exposed to 2,4 and 6 mg/kg cadmium concentration for 24, 48 and 72 h. The different letters shown on the graph represents the various groups studied and different statistically significant level. The values shown were the mean \pm SE at 95% ($p < 0.05$) statistically significant level.

DISCUSSIONS

Heavy metals contamination is an important concerned problem in not only aquatic organisms but also human being. When heavy metals such as cadmium are released into the environment, they can cause direct impact on living organisms. Various methods have been developed to evaluate health of aquatic animals such as fishes after exposed to heavy metals. Hinton et al. (1992) suggested the analysis of alteration in fish tissues could be used as an indicator for toxic chemical exposure and most importantly, where it had beneficial to evaluate the alteration in selected tissue of interest after living organisms had been exposed to different chemicals.

Other studies suggested that bioaccumulation and spread of cadmium were different in each organ of living organisms (Woo et al., 1993; Cattani et al., 1996). According to Wu et al. (1999), different results from studies could be related to the concentration, periods of exposure, and affected organs. Kaoud et al. (2011) found that the effect of cadmium was different in each organ of tilapia (*O. niloticus*). However, the effect of cadmium in various concentrations and times of exposure on the changes in fish tissue has been reported.

Gill is the major organ responsible for respiration and maintaining the stability within teleost fish body (Genten et al., 2009). In this

study, histological alteration in gill of Asian sea bass exposed to cadmium at 2, 4, and 6 mg/kg for 24, 48, and 72 h, respectively, was observed. The result showed that the concentration of cadmium affects the alteration of gill, which overall causes damage including edema, hyperplasia, epithelial lifting, and partial fusion of lamellae. This finding is in agreement with Kaoud et al. (2011) who show the effect of cadmium at 10 mg/kg on gill of tilapia (*O. niloticus*). It has been shown that the alterations occur as edema, hyperplasia, cell death or necrosis, and fusion of lamellae. This result is also similar to that of Montaser et al. (2010), which shows histopathological alterations in gill, such as rupture of lamellae epithelium, degeneration of epithelium cell, and epithelium lifting of Sleek unicorn fish (*N. hexanthus*) lives in heavy metals contaminated area. Furthermore, Wangsongsak et al. (2007) determined gill of Siver barb (*Puntinus gonionotus*) exposed to cadmium for 30 and 60 days, and found no alteration of gill tissues at 30 days of exposure, while at 60 days of exposure the hyperplasia of secondary lamellae was observed.

Liver is an important organ in the assimilation of nutrient, production of bile, maintaining the body metabolic homeostasis and detoxification of fishes (Genten et al., 2009). When teleost fish exposed to heavy metals, the detoxification mechanism in the liver will try to reduce the toxicity and eliminate the toxic substance. Therefore, this study was focused on to investigate alterations of liver tissue in Asian sea bass exposed to cadmium at 2, 4, and 6 mg/kg for 24, 48, and 72 h, respectively. The alteration of liver tissue was observed with severely increased as the concentration of cadmium increased after 24 h of exposure. An occurrence of alterations can be evaluated by observing cell degeneration with vacuolation in the cytoplasm and enlargement of sinusoid, where cell death and necrosis have been observed after 72 h of exposure to cadmium at 6 mg/kg. The result corresponds to the study by Kaoud et al. (2010), which shows the change of liver cells shape together with necrosis in liver of tilapia after cadmium exposure. The result is similar

to another study on *Prochilodus lineatus* that shows the alterations of cells shape, the occurrence of cytoplasmic vacuolation, and necrosis in liver of fishes collected from heavy metals contaminated areas compared to non-contaminated areas (Camargo and Martinez, 2007). Wangsongsak et al. (2007) also reported the change in liver of Silver barb (*P. gonionotus*) exposed to cadmium chloride, including slightly swollen and a few lipid vacuoles in the cytoplasm of hepatocytes after one month of exposure, while more swollen hepatocytes with dilated nuclei, vacuolation, and necrosis in some areas of the liver are presented after three months of exposure. The similar result was also reported by Dyk et al. (2007), who found the change in liver of *O. mossambicus* after cadmium exposure included hepatocyte vacuolation and cellular swelling.

Stomach and intestine are important organs in food digestion and nutrient absorption in fishes (Genten et al., 2009). It was found that the swelling of goblet cells and goblet cells amount increased after Asian sea bass had been exposed to cadmium. Lesions were found in cells and the severity levels increased according to the concentrations of cadmium received. An increase of cell lesion and wounds occurred in relation to an increase concentration of cadmium exposure for stomach of Asian sea bass that exposed to cadmium. The alteration of intestine and stomach is similar to results of the study by Kaound et al. (2011), which show the change of goblet cell basement membrane, such as secretory cell damages and cell death (necrosis) in stomach and intestine of tilapia (*O. niloticus*) exposed to cadmium when compare to that of the control group.

Kidney is an important organ in teleost fish, which performs excretory and osmo-regulatory functions in the body (Genten et al., 2009). Some histopathological alterations of kidney caused by cadmium have been observed. Kaoud et al. (2011) reported the change of tilapia (*O. niloticus*) kidney tissue, such as hydopic swelling of renal tubules, many necrotic area as well as swollen proximal epithelial cells after cadmium exposure. The similar alteration was observed in this study included the

disfiguration of tubular cell shape, increasing of Bowman's space, cell degeneration and accumulation of vacuole, and eventually cell death. It was in agreement with the study by Wangsongsak et al. (2007) which reported the widen lumen and mild swelling of proximal tubules in Silver barb (*P. gonionotus*) kidney after two months of cadmium exposure and the severe swelling tubules together with many necrotic areas after three months of exposure, while no alteration was observed after one month of exposure.

Several studies have been conducted on the effect of acute and chronic cadmium exposure in aquatic organisms. Bernet et al. (1999) recommended that histology could represent a useful tool to assess the contamination degree in the environment. The protocols of fish histological alteration study was established and applied to assess aquatic pollution. In the present study, it was found that exposure time and concentration factor had effect on injury index. Kidney showed the highest injury index as compared to all treatments similar with the study of *H. malabaricus* after exposed to methyl mercury by dietary exposure (Mela et al., 2007). It is well known that the primary organ for detoxification of heavy metal is liver (Wangsongsak et al., 2007), and cadmium is subsequently transported to kidney which is the main site for cadmium storage, and thus the tissue of kidney shows the highest damage. Therefore, kidney is the main organ which is susceptible to histological alteration after exposure to cadmium.

Melanomacrophage centers (MMCs) are characteristic typing of pigment-counting cells inside the heterothermic tissues of vertebrate, but may vary upon species (Agius and Robert, 1981). MMCs counting increased significantly compared to control with 95% ($p < 0.05$) after Asian sea bass exposed to $CdNO_3$ in all treatments. The incidence of MMCs counting, as observed here in Asian sea bass, was also observed in *O. mykiss* after 10 days of exposure to $CuSO_4$ and Cu-NPs (Al-Biruty et al., 2013). Mela et al. (2007) demonstrated that neotropical fishes (*H. malabaricus*) increased in number of MMCs after exposure to methylmercury for 70 days. An

increase of MMCs in *H. malabaricus* exposed to methylmercury recommended the presence of dead cell or replacement of red blood cells in kidney. According to the prevalence of MMCs counting in kidney, it is a potent biomarker of heavy metal contamination in fish. No significant alteration was detected as compared in each exposure time, which it might be caused by inadequate exposure time or cadmium dose that was at sublethal level.

In conclusion, cadmium exposure of Asian sea bass resulted in the alteration of organs comprising gill, liver, kidney, stomach and intestine. The lowest concentration of cadmium exposure was at 2 mg/kg, which showed slightly alteration in all tested tissues, while those fishes exposed to cadmium at 4 and 6 mg/kg, respectively, showed the adverse effect of tissue alteration. The highest of injury index and MMC counting occurred in kidney. This finding indicated the potent of kidney as the useful organ to evaluate cadmium contamination in fish.

ACKNOWLEDGEMENT

This work was supported by grant from the center of excellence on environmental health and toxicology, Bangkok, Thailand and Environmental Science Program, Faculty of Science, Burapha University.

REFERENCES

- Al-Biruty, G. A., Shaw, B. J., Handy, R.D. and Henry, T.B. 2013. Histopathological effects of waterborne copper nanoparticles and copper sulphate on the organs of rainbow trout (*Oncorhynchus mykiss*). *Aquatic Toxicology* 126: 104-115.
- Agius, C. and Robert, R.J. 1981. Effects of starvation on the melano-macrophage centers of fish. *Journal of Fish Biology* 19: 161-169.
- Athauda, S., Anderson, T., and Nys, R. D. 2012. Effect of rearing water temperature on protandrous sex inversion in cultured Asia sea bass (*Lates calcarifer*). *General and Comparative Endocrinology* 175: 416-423.
- Bernet, D., Schmidt, H., Melier, W., Burkhardt-Holm, P., and Washli, T. 1999. Histopathology in

- fish: proposal for protocol to assess aquatic pollution. *Journal of Fish Diseases* 22: 25-34.
- Brucka-Jastreżbska, E. and Protasowiki, M. 2006. Changes of cadmium content in various organs of common carp (*Cyprinus carpio* L.) during the fast growth period following initial rearing in contaminated water. *Archives of Polish Fisheries-index Copericus Journal* 14: 183-194.
- Camargo, M.M.P. and Martinez, C.B.R. 2007. Histopathology of gills, kidney and liver of a Neotropical fish caged in an urban stream. *Neotropical Ichthyology* 5(3): 327-336.
- Cattani, O., Serra, R., Isani, G., Raggi, G., Cortesi, P., and Carpena, E. 1996. Correlation between metallothionein and energy metabolism in sea bass, *Dicentrarchus labrax*, exposed to cadmium. *Comparative Biochemistry and Physiology Part C* 113(2): 193-199.
- Cheong, L. 1989. Status of knowledge on farming of sea bass (*Lates calcarifer*) in South East Asia. *Advances in Tropical Aquaculture Tahiti* 9: 421-428.
- Dyk, J.C.V., Pieterse, G.M., and Vuren, J.H.J.V. 2007. Histological changes in the liver of *Oreochromis massambicus* (Cichidae) after exposure to cadmium and zinc. *Ecotoxicology and Environmental Safety* 66: 432-440.
- Genten, F., Terwinghe, E., and Danguy, A. 2009. *Atlas of Fish Histology*. Science Publisher, New Hampshire.
- Hinton, D. E., Baumann, P. C., Gardner, G. R., Hawkins, W. E., Hendricks, J. D., Murchelano, R.A. and Okihiro, M. S. 1992. Biomarkers: biochemical, physiological, and histological markers of anthropogenic stress, pp. 155-209. In Huggett, R. J., Kimerle, R.A., Mehrle, P. M., Jr. and Bergman, H. L. (ed.). *Histopathologic Biomarkers*, Lewis Publishers, Chelsea.
- Jayakumar, P. and Paul, V.I. 2006. Patterns of cadmium accumulation in selected tissues of catfish *Clarius batrachus* (Linn.) exposed to sublethal concentration of cadmium chloride, *Veterinary Archive* 76 (2): 167-177.
- Kaoud, H.A., Zaki, M., El-Dahshan, A., Saeid, S., and ElZorba, H.Y. 2011. Amelioration the toxic effects of cadmium-Exposure in Nile Tilapia (*Oreochromis niloticus*) by using *Lemma gibba* L. *Life Science Journal* 1: 185-195.
- Kumar, P. and Singh, A. 2010. Cadmium toxicity in fish: An overview. *GERF Bulletin of Biosciences* 1(1): 41-47.
- Mela, M., Randi, M.A.F., Ventura, D.F., Carvalho, C.E.V., Pelletier, E. and Ribeiro, C.A.O. 2007. Effect of dietary methylmercury on liver and kidney histology in the neotropical fish *Hoplias malabaricus*. *Ecotoxicology and Environmental Safety* 68: 426-435.
- Montaser, M., Mahfouz, M.E., El-Shazly, S.A.M., Abdel-Rahman, G.H., and Bakry, S. 2010. Toxicity of heavy metals on fish at Jeddah coast KSA: Metallothionein expression as a biomarker and histopathological study on liver and gills. *World Journal of Fish and Marine Science* 2(3): 174-185.
- Okocha, R.C. and Adedeji, O. B. 2011. Overview of cadmium toxicity in fish. *Journal of Applied Sciences Research* 7(7): 1195-1207.
- Ruangsomboon, S. and Wongrat, L. 2006. Bioaccumulation of cadmium in an experimental aquatic food chain involving phytoplankton (*Chorella vulgaris*), zooplankton (*Moina macrocopa*), and the predatory catfish *Clarias macrocephalus* X *C.gariepinus*. *Aquatic Toxicology* 78: 15-20.
- Vinodhini, R. and Narayanan, M. 2008. Bioaccumulation of heavy metals in organs of freshwater fish *Cyprinus carpio* (Common carp). *International Journal Environmental Science and Technology* 5 (2): 179-182.
- Wangsongsak, A., Utranpongsa, S., Kruatrachue, M., Ponglikitmongkol, M., Pokethitiyook, P., and Sumranwanich, T. 2007. Alteration of organ histology and metallothionein mRNA expression in silver barb, *Puntinus gonoonitus* during subchronic cadmium exposure. *Journal of Environmental Science* 19: 1341-1348.
- Woo, P.T.K., Sin, Y.M. and Wong, M.K. 1993. The effect of short-term acute cadmium exposure on blue tilapia, *Oreochromis aureus*. *Environmental Biology of Fishes* 37: 67-74.

- Wu, S.M., Weng, C.F., Yu, M.J., Lin, C.C., Chen, S.T., and Hwang, P.P. 1999. Cadmium-Inducible Metallothionein in tilapia (*Oreochromis mossambicus*). *Physiological and Biochemical Zoology* 73: 531-537.

มหาวิทยาลัยบูรพา
Burapha University